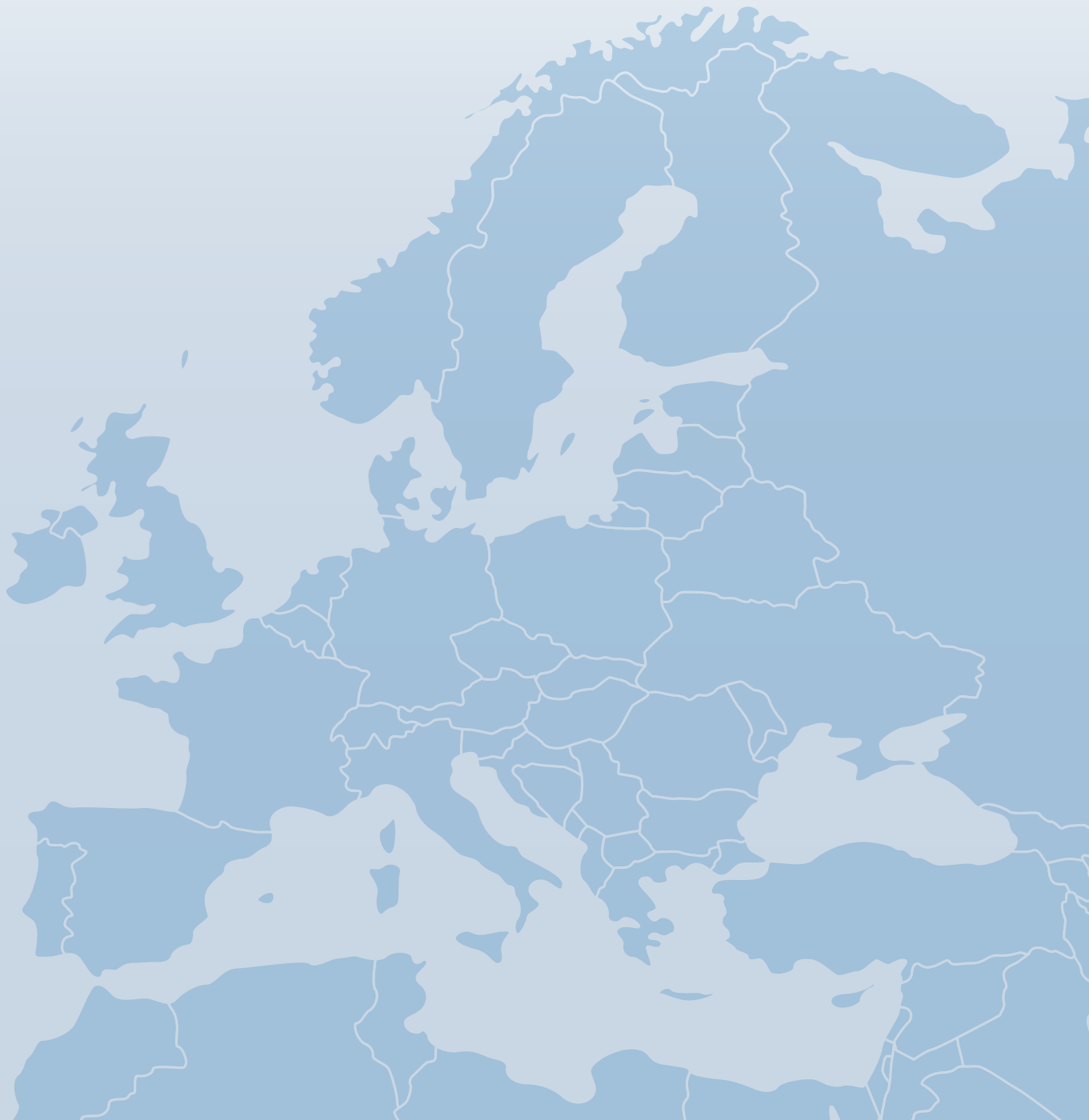

EPOS NEWSLETTER



European Paediatric Orthopaedic Society · DECEMBER 2015



www.epos.org

Welcome Address



Dear All,

We are happy to provide you with the most recent newsletter of our European Paediatric Orthopaedic Society.

The "winter version" consists of several topics which hopefully will pique your interest.

We will have a look at "What`s going on in other societies", get some "Tips and Tricks in Paediatric Orthopaedics" from a real expert in the field and our JCO Editor stimulates your research interest with some article summaries from the two most recent Journals of Children`s Orthopaedics, our societies own booklet.

Enjoy and have a wonderful winter time !

Best wishes



Dr. Stephanie Boehm

EPOS board member

Consultant Paediatric Orthopaedic Surgeon

Astrid Lindgren Children`s Hospital

Karolinska University

17176 Stockholm

Sweden



Index



Welcome
PAGE 2

02

President`s address
PAGE 3

03

The National Society Page
PAGE 4-5

04

EPOSNA Barcelona 2017 - update
PAGE 6

06

National Societies:
What`s going on in...Torino?
Torino: 7th Pediatric Orthopaedic
Trauma Congress
PAGE 7

07

National Societies:
What`s going on in...Dubai?
Brief Report on
The 2nd MEPOS Annual Meeting
PAGE 8 - 9

08

EPOS RCCG Georgia Report
PAGE 10

10

Interesting topics in JCO:
a summary
PAGE 11-12

11

Tips and Tricks in
Paediatric Orthopaedics
The limping child
PAGE 13-14

13

President's address



B Møller-Madsen MD DMSci
Current EPOS President

Dear members of EPOS, dear colleagues and friends,

It is a great honour and pleasure for me to be the President of our Society 2015 – 2016. I thank you for giving me the mandate. I will do my best. However, leading EPOS today is teamwork, and I am optimistic having highly qualified colleagues sitting next to me in the Board.



It has been a long journey for me starting in 1994 as a senior registrar at our National Hospital in Copenhagen, Department of Children's Orthopaedics.

I was literally ordered to attend the 13th Annual Meeting by a previous President of our Society, Jørgen Reimars.

The Meeting took place at Hotel Solverde in Espinho, Portugal 1994 very close to the Atlantic sea. Dr. Mesquita Montes was local host and organiser.

I still remember the atmosphere at that time given by the combination of listening to scientific presentations a full day then sipping vintage port wine in the evenings. From then on I was addicted to EPOS meetings - and I have not missed a single congress since then.

I became a full member in April 1996 at Hotel Ambassador, Prague where Pavel Dungl was local host and Klaus Parsch was president.

I still remember Pavel apologising for the snow falling in the streets of Prague during our city walk.



Ever since 1994 EPOS meetings have been a kind of "pit stop" for me - I felt I was

given useful updated knowledge which I could go back and offer the children in Denmark right away. Besides that, the meetings became an opportunity to meet old friends and make new friendships. This has not been changes through the years gone.



Having that in mind I feel that our Society during the years from Espinho until today has been transformed from an adolescent child, whatever that means, to a full grown mature and strong player in Europe with an iconic brand.

Our society is committed to improving the health of children everywhere by supporting members to build on evidence-based practice. We will continue to do so.

However, I think we have to be instinctive digital, when planning our next steps forward e.g. e-learning and web development. We have in our EPOS BAT Educational Programme a proven solid ground to build on.

The National Society Page



Pierre Lascombes
EPOS Past President

Last April 2015 in Marseille, Elke Viehweger managed a poster presentation of the National Society (NS). The goal was to offer each country to present its own Paediatric Orthopaedic Society, and to detailed the way to become a paediatric orthopaedic surgeon. Some NS exposed their own poster in the main hall, and we would like to thank them again (from top left):

- Belgium, Croatia, Czech Republic, France, German speaking (Germany, Austria and Switzerland), Israel
- Italy, Kosovo, Lebanon, Norway, Poland, Portugal
- Romania, Spain, Sweden, Turkey, Switzerland and UK
- In addition Australia, Brazil, and Middle East were also present.

May I wish that more NS contribute to these exchanges?

Today, we would like to honour Italy and the SITOP as the next EPOS annual meeting will held in Rome next April 2016, and also Portugal and the SEOI as Manuel Cassiano-Neves is the next EPOS President. We hope in the future still more combined activities between EPOS and the NS. One of the most important goal is education of Paediatric Orthopaedics. Best wishes



The National Society Page



Cristina Alves

Head of the EPOS Scientific committee/member EPOS Reading committee

In March 1980, the Orthopedic Surgeons from Oporto Children's Hospital Maria Pia, Dr. Côrte-Real, Dr. Mesquita Montes, Dr. Lino Ferreira and Dr. Vieira Coelho, organized the first Children's Orthopedics Conference in Portugal. In 1982, Dr. Mesquita Montes participated in the foundation of the European Pediatric Orthopaedics Society (EPOS). On May 10th 1983, SEOI (Secção para o Estudo

da Ortopedia Infantil) was created, following the Proposal for a Regulation of the Section of Children's Orthopedics, signed by Dr. Arthur Côrte-Real, disseminated to the members of SPOT (Portuguese Society of Orthopaedics and Traumatology).

[\(Read more...\)](#)



Maurizio De Pellegrin
(S.I.T.O.P)

ABOUT US:

The Italian Society of Pediatric Orthopedics and Traumatology (S.I.T.O.P) was founded December 11, 1982 at Rizzoli Orthopedic Institute of Bologna, by 17 orthopedic surgeons with a special interest in this field. Their aim was to promote knowledge and improve clinical management, teaching and research of pediatric orthopedics. In 1985, the Society held its first National Congress and

published the first issue of the Journal of the Italian Society of Pediatric Orthopedics and Traumatology. In the past years, the Society has stimulated the exchange of ideas and experiences among Italian and foreign specialists. Within the Society, many Study Groups have been

[\(Read more...\)](#)

EPOSNA Barcelona 2017 - update

EPOSNA BARCELONA 2017 - UPDATE



Dr. Manuel Cassiano Neves
EPOS President Elect 2016-2017



After hard work from the former Presidents, Muharrem Yazici, Deborah Eastwood and Pierre Lascombes

EPOS and POSNA were able to settle the Foundations of what will be expected to be the largest meeting of Paediatric Orthopaedics ever. The meeting will take place at the "Palau de Congressos de Catalunya" in Barcelona and will be held between the 3rd and the 5th of May 2017.

In order to proceed with the organization a meeting took place in Barcelona in the first week of DECEMBER 2015. It was a combined meeting between the EPOS and POSNA representatives From EPOS Manuel Cassiano – 2017 President, Pierre Lascombes - Member of the original planning Committee, Bjarne Moller Madsen – 2016 President, Darko Anticevic - EPOSNA Program Co-Chair, Deborah Eastwood - Member of the original planning Committee, Robi Valkhoff - CAOS CEO, Jorge Knörr - local organizer, and from POSNA, Jim McCarthy, 2017 President, Tony Stans, 2017 EPOSNA Program Co-Chair, Peter Newton, Member of the original planning Committee, Peter Waters, Member of the original planning Committee, Cristina Cabral-POSNA Society



Manager, Joy Cmiel, Conference Direct and Teri Stech-POSNA Society Director

Since there are some differences between the annual meetings of both organizations it was imperative to combine both scientific programs into one single format. From the EPOS side Darko Anticevic, the current chair of the Reading Committee, will be leading the scientific program. The pre-course meeting will be jointly organized by EPOS and POSNA and Rudolf Ganger will be leading this project.

The meeting went in a friendly atmosphere and all the members of the organizing committee are excited with this joint venture. We hope that you will be involved with this project as much as we are. It will be an excellent opportunity to show

the orthopaedic world the state of the art in Europe. In order to support our members, EPOS will dedicate special sessions in Rome dedicated on "how to conduct a study" and how "to get my abstract accepted..." in order to increase the visibility of EPOS in the meeting. So please save the dates on your calendar so we can meet in Barcelona 2017.

National Societies: What`s going on in...Torino?



TORINO: 7TH PEDIATRIC ORTHOPAEDIC TRAUMA CONGRESS



Antonio Andreacchio
EPOS Reading Committee

From 4th till 6th of June held in Turin the 7th edition of the Pediatric Trauma Meeting under Antonio Andreacchio presidency.

More than 150 participants have registered this year and more than 1300 members attended the event in 7 years.

This Congress every year in Turin since 2009 is an occasion for the Italian orthopaedic surgeons to review and upgrade their knowledge on every kind of fracture in childhood.

At the beginning this meeting was addressed to the general adult orthopaedic surgeons who had to face with the pediatric trauma in their daily clinical practice but year by year thanks to an high faculty level it has becoming a pediatric orthopaedic meeting point as well.

Since 2009 the main foreign host is Prof Pierre Lascombes who spreaded the principles and application of the elastic stable intramedullary nails of the Nancy school all over the world and even this year he spoke about this method for the treatment of the long bone fractures in children.

Since 2013 Thomas Wirth joined him in the faculty taking some podium presentation on elbow fracture, pitfalls in pediatric fractures and Osteogenesis imperfecta fractures treatment.

This year the third foreign invited host was Federico Canavese who works at Clermont Ferrand in France.

During these 7 years from the podium we had a large turn over of speakers such as Hank Chambers from San Diego, USA, Nando de Sanctis and Ernesto Ippolito from Italy past EPOS Presidents, Mikhail Samchukov from Texas Scottish Rite, Dallas, USA, Vincenzo De Rosa from Bellinzona, Switzerland and almost all the Italian EPOS members.


The congress lasts 2 and half days: from Thursday morning till Saturday afternoon. The sessions include generality on fracture healing process and physeal fractures, radiologic session, upper and lower limb fractures, principles and treatment of the children fractures by elastic stable intramedullary nails and external fixators, round table about the child and the sport, 2 case clinic interactive sessions, hand surgery session.

On late friday afternoon every year not missing a moment dedicated to be together and to visit some monument or museum of the city of Turin, this year it was the turn of the visit to the Holy Shroud which was exceptionally exposed for the EXPO 2015.

A social dinner on the friday evening is a nice event for every attendee.

The right mix between senior faculty, hot spot topics, round table, case report sessions, long time to discuss every communication is the recipe that allowed the success of this event for all these years.

National Societies: What`s going on in...Dubai?



BRIEF REPORT ON THE 2ND MEPOS ANNUAL MEETING 8-10 OCTOBER, 2015. DUBAI, UAE



Darko Anticevic
EPOS Vice President

In the first half of October 2015, Dubai, UAE was the host city of 2nd MEPOS (Middle East Pediatric Orthopaedic Society) Annual Meeting and 4th Pediatric Orthopaedic Surgery conference (POSC) which was chaired by MEPOS General Secretary Dr. Marc Sinclair ([pict. 1](#)) and co-chaired by 2nd EPOS Vice-President Professor Darko Anticevic.

Guiding Growth Flex Tack and Rigid Tack, 4. Implantable Lengthening Devices, 5. Osteotomy of the Proximal Femur in Children – Hip Locking Plates and cannulated Blade Plate. Those issues were well covered and in addition supplemented with two workshops ([pict.2](#)).



Pict 1. Marc Sinclair, Chairman 2nd MEPOS/4th POSC Dubai




Pict 2. Workshop participants on 2nd MEPOS/4th POSC Dubai

Pre-Conference Courses were aimed to shed more light to five topics: 1. Alternative Fixation of the Spine, 2. Complex Issues on Foot Deformity, 3. The Next Step in

Main Conference consisted of Day 1 which was devoted to Upper Extremities in Children with four sessions of invited lectures and one session of free papers ([pict3](#)).

National Societies: What`s going on in...Dubai?



*Pict 3. Round table faculty. from the left to the right:
Peter Waters, Darko Anticevic, Andrea Bauer, Marc Sinclair,*

In feed-back evaluation more than 80 percent of participants made excellent and very good scores as per scientific and professional level of 2nd Annual MEPOS meeting.


In conclusion, EPOS should help to promote and to increase level of service for children with musculo-skeletal health issues in the region of Middle East and the society such as MEPOS.

The topic of Conference Day 2 was Neuromuscular Diseases in Children with four sessions of invited lectures and one session of free paper with a total number of 165 participants. There were 29 invited speakers from 11 countries. Five EPOS countries and speakers has representatives at 2nd MEPOS: Marc Sinclair (United Arab Emirates), Zaid Al Aubaidi (United Arab Emirates), Gamal Hosny (Egypt), Robert Roedl (Germany), Jan Charvat (Czech Republic) and Darko Anticevic (Croatia).

EPOS RCCC Georgia Report



Dr. Elhanan Bar-On MD, MPH
Core Curriculum Courses Coordinator



The sixth EPOS Regional Core Curriculum Course was given in Tbilisi – Georgia on June 5-6 2015. Previous courses were in Kosovo, Albania, Lithuania, Bosnia-Herzegovina and Romania.

The Regional Core Curriculum Course program is one of the educational endeavors of EPOS aiming to provide basic education in pediatric orthopedics in the peripheral regions of Europe. In some of these regions pediatric orthopedics has not yet branched off as a distinct subspecialty and children are treated by general orthopedists or trauma surgeons. In addition, the orthopedic surgeons who do treat children find it difficult to attend the EPOS meetings. With this in mind, the EPOS RCCC program was initiated, presenting a theoretical wide coverage of pediatric orthopedic problems with in depth interactive case discussions.

The course was attended by 43 local registrants. 22 participants came from Georgia, 13 from Armenia, 5 from Azerbaijan and 3 from Lithuania. Most participants were orthopedic surgeons and residents. The course was coordinated by Elhanan Bar-On (Israel) with local hosts Dr. Lasha Dzidziguri from Georgia and Dr. Garen Koloyan from Armenia. The faculty included EPOS secretary Dr. Ralph

Sackers (Netherlands), past presidents Dr. Deborah Eastwood (UK), Prof. Muharrem Yazici (Turkey) and prof. Elhanan Bar-On (Israel). The course content was based on a core curriculum covering trauma, hip, foot, limb deformity, spinal deformity, neuromuscular problems, infections and skeletal dysplasias. Case discussions were held both on cases brought by the faculty and those presented by local participants. This course content has evolved based on previous course experience and feedbacks as well as pre-course consultations with the local hosts regarding the specific interests of the local participants.

The feedback received from the participants and organizers was excellent and encourages us to continue this endeavor.

Future courses are being planned in Bulgaria, Serbia and Russia.

Interesting topics in JCO: a summary



Fritz Hefti, M.D., Professor
Editor-in-Chief of the Journal of Children's Orthopaedics

Open questions that find answers in the latest issues of JCO (9-4 and 9-5, now online available)

The editors of the Journal of Children's Orthopaedics try to accept only articles that bring some new knowledge to the community of people who are involved in the treatment of children with problems on their locomotor apparatus. EPOS news is now publishing a brief report on the open questions that find answers in the newest issues. Hopefully we can motivate the members of the society to read these articles.

In issue 9-4 11 articles are published. Among these the following interesting questions are raised:

Among the various theories about the etiology of LCPD, which is much more common in boys, the activity level never was a major issue so far. Is this also true for girls? If you want to know more about this, read the article of Georgiadis et al..

If we have to treat a child with a congenital limb deficiency with an orthosis or a prosthesis, we usually concentrate our attention to the affected part of the limb. Did you ever ask yourself, what happens with the underused ipsilateral healthy hip? The article of Sallam et al. gives answers with the help of instrumented gait analysis.

There is a lot of debate about what to do with a painful chronic hip dislocation in cerebral palsy patients. Should the hip be reduced, should it be left alone or the femoral head be excised? The article of

Patel et al. reports on the results of head excision and an amplified interposition myoplasty in 11 patients with an average of 4.5 years of follow-up time.

Children with hand defects often cope astonishingly well with their impairment. Playing is the best motivator for them to develop social and household skills. A special program using play therapy can further improve their abilities. The article of Klimon et al. reports the results of such a treatment in a large number of 122 patients.

It is common knowledge that intermittent distraction at or parallel to the spine can stimulate growth of the vertebral bodies in lengths. The article of Hasler et al., however, brings fundamentally new knowledge about the changes of the shape of the vertebral bodies after such stimulation.

Parents are rightly worried about the radiation dose of x-rays. It is therefore an important task to reduce the number of unnecessary x-rays. The article of Schlechter et al. gives advice about the question, when x-rays after supracondylar humeral fractures are necessary and which x-rays can be left out.

In children with suspected septic arthritis of the hip it is often frustrating that aspiration of intraarticular fluid does not reveal positive cultures. The article of Schmale and Bompadre shows that in such cases it is rewarding to do aspirations from the ilium and the proximal femur.

One of the most debated topics in paediatric

Interesting topics in JCO: a summary



orthopaedics is the question, how to treat congenital tibial dysplasia (previously known as congenital pseudarthrosis of the tibia). Until now very little attention was given to the long term prognosis of the proposed methods. The article of Vanderstappen et al offers a follow-up study with an average of 24.5 years observation time on 12 patients, which gives this article a special value.

In the most recent issue 9-5 (13 articles) we also can find some specially interesting publications:

One of the aims of the WHO is to globally eradicating polio. However, until now this is not fulfilled. On the contrary, fresh outbreaks of polio have been reported in this century not just from parts of the developing world but even from countries previously declared polio-free. The current concept article of Benjamin Joseph is therefore of great value. The author is an authority in this field, which was the greatest challenge for orthopaedic surgeons 50 years ago. With the decline of the incidence of the disease the knowledge about useful and ineffective treatment methods disappeared. This article brings light in the dark.

Obstetric brachial plexus paresis has become less common with the increase of Cesarean sections, but still exists. C5-C6 injury may lead in some cases to adduction – internal rotation shoulder contracture. Subscapularis contracture may prevent a functional rotator cuff from acting normally to produce optimal active shoulder abduction and external rotation, and releasing it may eliminate an obstacle to such shoulder function. The paper of Melhem et al. shows the benefits and complications of proximal subscapularis release in such patients. Patients with severe neuromuscular scoliosis have an increased for pneumonia. The hope is that scoliosis surgery decreases the incidence of pneumonia in such patients. The article of Keskinen

et al. gives answers to this important question.

Caput valgum is a common consequence associated with avascular necrosis after developmental dysplasia of the hip. Can this be successfully treated with transphyseal screw fixation? Young et al. give the answers.

Deep venous thrombosis and pulmonary embolism in paediatric orthopaedic trauma patients is very rare but exists. It is therefore very interesting to know about the incidence on a national scale in USA. The article of Murphy et al. presents the answers.

Intraarticular knee fractures in children are rare. The main problem is that very often the diagnosis is missed at the initial examination. The study of Leeberg et al. indicates that initial recognition of the extent of injury is the key parameter to prevent missed diagnosis with delayed and potentially more difficult surgery with long lasting sequelae for the child to follow knee in children.

Patients with multiple osteochondromas often have a short stature. Both the local effect on growth plates and the systemic influence of the gene disorder on growth mechanisms might explain the diminished stature. The article of Staal et al. gives us answers on the potential part of the systemic influence on growth.

For leg shortening the transcutaneous epiphyseodesis according to Canale has become a standard method. The technique of percutaneous epiphysiodesis using transphyseal screws is less commonly use. The article of Aronsson et al. reports us about the reliability of this method.

Harvesting autologous iliac crest bone graft is a commonly used procedure in paediatric orthopaedics. However, we know little about the complication rate of this operation. In a prospective study Jones et al. have reviewed the side effects of this procedure.

Tips and Tricks in Pediatric Orthopaedics



TIPS FOR EVALUATION OF THE TODDLER WITH A LIMP



Scott Mubarak, MD

*Clinical Professor of Orthopaedics
Rady Children's Hospital and
University California, San Diego*

History: *When a toddler (1-4 years) presents with a recent onset of a limp, the differential diagnosis is primarily between trauma and infection. Often these two entities can be sorted out by a careful history: was there immediate onset of pain following a witnessed injury?*

If there was a delay in the onset of the limp or pain or history of trauma is unclear, infection or synovitis is more likely. (Did the child cry out and not walk immediately after the fall?) Worsening of the symptoms would add support for an inflammatory process rather than trauma. Fever and loss of appetite again would support an inflammatory cause. Discitis, arthritis or a malignancy are more unusual causes.

How long has there been a limp? Which side do the parents believe is involved? Is the child walking? And importantly, if not- can the child crawl?

At this point there is a rush for diagnostic tests: radiographs, blood tests and MRI. Often I hear on morning rounds, "the child can't walk and the sedimentation rate and CRP are elevated, therefore we ordered an MRI." The young physician omits or minimizes the next step: physical examination.

Examination: *This should be done gently and quietly on the parent's lap (Figure 1). If feasible I try to*

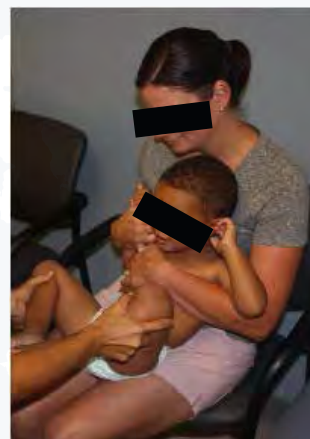do this before the technician with needle approaches

the child for blood tests. Try to rule out hip disease by a gentle flexion and abduction of the hips. Record your findings!

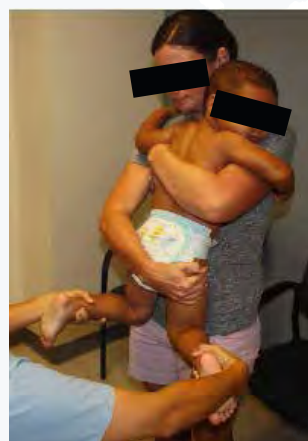Palpate the back

(discitis), trochanters and pelvis.

Then move distally and palpate the distal femurs, tibias and feet.



(Figure 1)



(Figure 2)

Two helpful tests are:

- 1. Prone internal rotation of the hip (Figure 2). For a toddler this is best done with the child being held by the parent (chest to chest) with hips fully extended. The prone position increases joint pressure by*

Tips and Tricks in Pediatric Orthopaedics



TIPS FOR EVALUATION OF THE TODDLER WITH A LIMP

extending the hips and decreasing the volume of the joint capsule. Furthermore this position provides a more accurate measure of the hip's internal rotation compared to the normal side by stabilizing the child's pelvis. This is the most sensitive indicator of hip joint involvement for disorders ranging from synovitis, arthritis, Perthes, to septic hip.

2. Crawl Test (Figure 3): In some cases the child may stand or even take a few steps. This will be most useful for lateralization and localization of the pathology. If the child will not stand, can you entice the child to crawl? If by history or by exam a reciprocal crawl is possible, the pathology is distal to the knee!



(Figure 3)

Pelvis osteomyelitis, hip and knee sepsis are extremely unlikely. The Crawl test narrows the location of the pathology to the tibia and feet. This is a most useful finding. Your imaging studies can now be limited to those areas.

Radiographs: My six views for a limping child without localization are as follows:

AP and frog pelvis (omit these films if normal hip motion and symmetrical crawling is possible)

AP both tibias together

Lateral of each tibia to include the knee and foot

AP of both feet together

With a child able to crawl the most common diagnoses for a limping child would be: tibia (toddler) fracture, osteomyelitis of the distal tibia, cuboid compression fracture, osteochondritis of the foot (Kohlers, etc) or foreign body in the foot. If the diagnosis is not made then blood tests and MRI may be indicated.

Good luck and hopefully these suggestions help.

smubarak@rchsd.org

