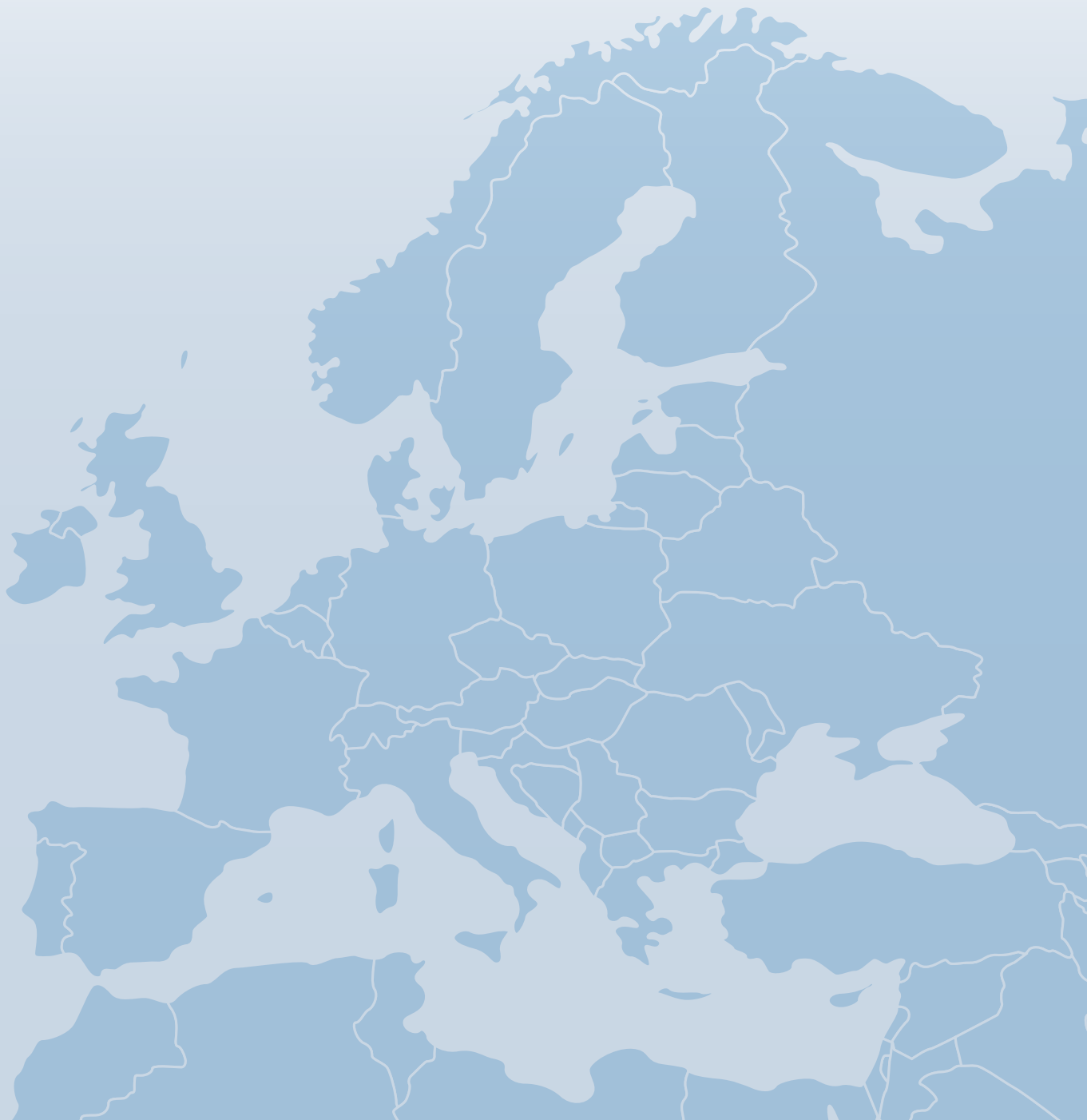

EPOS NEWSLETTER



European Paediatric Orthopaedic Society · JANUARY 2019



www.epos.org

Welcome Address



Dear EPOS members

I am happy to provide you the next winter edition of our EPOS newsletter.

Prof. Jarek Czubak, our current EPOS president, will inform you about the work within our society boards. Please catch up tips and tricks on the paediatric hand, receive summaries of what was going on in our society and enjoy our picture quiz.

Don't forget to joint our next EPOS meeting in Tel Aviv, Israel which gets really close!

Finally, you are kindly invited to discuss with us the question "In The Age Of Social Media, Should You Be Bothered With E-Newspapers?"

I wish you all the best for 2019 from Austria!



Renata Pospischill MD

EPOS board member

*Consultant Paediatric Orthopaedic Surgeon
Orthopaedic Hospital Vienna Speising
1130 Vienna
Austria*



Index



Welcome
PAGE 2

02

A word from Jaroslaw Czubak
PAGE 3

03

Tips and tricks in... Hand Surgery
Syndactyly release [...]
PAGE 4-5

04

EPOS Annual Meeting 2018 in Oslo
PAGE 6-7

06

5th EPOS-EFORT BAT Course:
Paediatrics Basic II - October 2018
PAGE 8

08

13th International Chinese
Orthopedic Association Congress
PAGE 9-10

09

Upcoming Activities
January-April 2019
PAGE 11

11

Picture Quiz
What is your diagnosis?
PAGE 12

12

In the age of social media, should you
be bothered with e-newspapers?
PAGE 13

13

Presidential Letter - A word from Jaroslaw Czubak



Jaroslaw Czubak

European Paediatric Orthopaedic Society
President 2018-2019

Dear colleagues,

The current President of the European Society for Children's Orthopaedics is already halfway through the term of office.

EPOS is growing and developing:

- We have a modern office, thanks to which the work of Executive Committee members has become more efficient, there is a good exchange of information which maximizes efficiency.
- We are continuing our BAT trilogy courses with the hospitality of the Orthopaedic Hospital Vienna Speising.
- We are already preparing our annual meeting, which will take place on 3-6 April 2019 in Tel Aviv, Israel. The awesome activities of our members, especially of the EPOS Study groups, will complement the program with satellite sessions during the annual meeting.
- Because of the enormous interest into the EPOS BAT Advanced Course concerning hip and pelvic surgeries in January 2019 in Geneva, we decided to repeat the course in January 2020.

In connection with the planned EPOSNA 2024 congress, we conducted a survey, the results of which showed that a significant majority of EPOS members support the idea of a combined meeting with POSNA, which will take place in the eastern part of the USA. An EPOS team was created to prepare this prestigious meeting. The work of the team will start at the end of 2018.

In the current term of office we have a new PCO, which is responsible for organizing annual EPOS congresses. The office has a contract for 3 years. PCO is also responsible for EPOS branding during EFORT congresses. Therefore, we had our booth in Barcelona, where everyone could find information about the scientific and educational activities of EPOS.

Our particular concern is the flow of information from ExCom to all members. At the last meeting of ExCom in Rolle, Switzerland, on the initiative of counsellors, we made efforts to change the current EPOS information formula, including the EPOS Newsletter. The main place of detailed information will be the EPOS website, but in order to speed up the flow of information we will start using social media.

The activity of members of our Society has caused overloading of our office, which on one hand makes us happy, and on the other hand may cause the need of increase the office's personnel costs.

The process of moving the formal EPOS headquarters from Prague to Rolle continues. The relocation process is necessarily handled by two law firms: Czech and Swiss. This process will be completed by the end of 2019. Then EPOS will have a tax exemption status and though will benefit from the privileges provided for such organisations.

At the end I would like to send you all my best wishes for a Happy 2019 New Year!

Tips and tricks in... Hand Surgery



SYNDACTYLY RELEASE IN THE PAEDIATRIC HAND



Sebastian Farr, MD

Consultant Paediatric Orthopaedic Surgeon
Orthopaedic Hospital Vienna Speising
1130 Vienna
Austria

Syndactylies in the pediatric hand are among the most common congenital hand malformations with an overall incidence of about 1.29 per 10,000 newborns¹. They are usually recognized directly after birth, although subtle syndactylies may stay unrecognized for a longer period of time.

Syndactylies may involve the entire finger (complete syndactyly), with or without nail and fingertip involvement, or only (proximal) parts of it (incomplete syndactyly). They may consist of soft tissue connections (simple syndactyly) or bony connections (complicated/complex syndactyly), and this fact hence warrants radiographic investigation at the time of presentation.

Surgical correction is generally indicated until latest two years of age to improve independent finger motion and thus hand function. To not operate is no reasonable option for this particular congenital malformation except for very subtle cases. However, border digits may need earlier separation (e.g. at 6-9 months of age) in order to avoid axial deviation and/or progressive finger flexion contracture development.

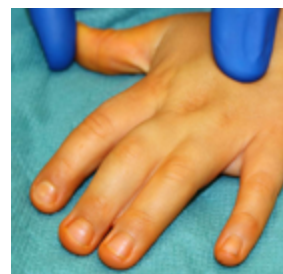In cases of double syndactylies (e.g. second to fourth finger), separation should involve only one side at a

1 Goldfarb CA, Shaw N, Steffen JA, Wall LB. The Prevalence of Congenital Hand and Upper Extremity Anomalies Based Upon the New York Congenital Malformations Registry. *J Pediatr Orthop.* 2017 Mar;37(2):144-148.

time in order to not jeopardize finger vascularity during surgical separation.

Surgical technique (simple syndactyly, Fig. 1):

Fig. 1: Preoperative situs of an incomplete, simple syndactyly



The extremity is washed and draped in a sterile fashion, and a tourniquet (HemaClear®, OHK Medical Devices, Inc., Grandville, MI, USA) is used for improved visualization.

Loupe magnification is essential for this kind of surgery. Several techniques have been described for finger separation, most of which involve a dorsal and a palmar flap, starting from the MP joints and following a zigzag fashion into the distal direction (Fig. 2)^{2 3 4}.

2 Ni F, Mao H, Yang X, Zhou S, Jiang Y, Wang B. The Use of an Hourglass Dorsal Advancement Flap Without Skin Graft for Congenital Syndactyly. *J Hand Surg Am.* 2015 Sep;40(9):1748-54.e1.

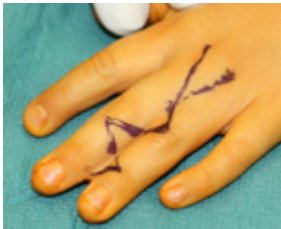3 Mallet C, Ilharberborde B, Jehanno P, Litzelmann E, Valenti P, Mazda K, Penneçot GF, Fitoussi F. Comparative study of 2 commissural dorsal flap techniques for the treatment of congenital syndactyly. *J Pediatr Orthop.* 2013 Mar;33(2):197-204.

4 Hsu VM, Smartt JM Jr, Chang B. The modified V-Y dorsal metacarpal flap for repair of syndactyly without skin graft. *Plast Reconstr Surg.* 2010 Jan;125(1):225-32.

Tips and tricks in... Hand Surgery



Fig. 2: The skin incision follows a zigzag fashion, with a reciprocal direction of similar flaps on the palmar side



It is important that any skin incision does not violate the finger commissure. In cases with fused fingertips, a Buck-Gramcko plasty is indicated for distal soft tissue separation⁵.

Fig. 3: The local flaps are carefully raised. It is imperative to be aware of the anatomic situation of the neurovascular bundle.

After skin incision marking, the skin flaps are carefully raised. It is important not to harm the peritendineum and its supplying vessels (Fig. 3).

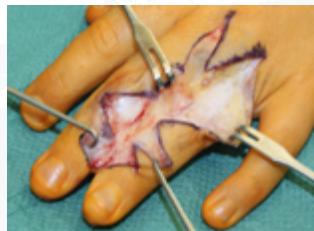
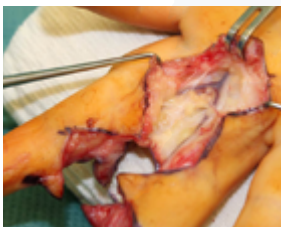
Fig. 4: The neurovascular bundles are exposed incl. their bifurcation

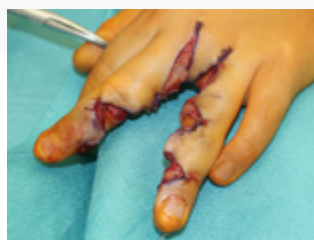

The soft tissues are carefully separated and the neurovascular bundle is exposed, although dissection should be limited to exposing the area of bifurcation proximally (Fig. 4).

Whenever the bifurcation of the vessels is relatively distal, careful ligation of one side is necessary to allow for proper digital separation. Ligation using the bipolar cautery should be far enough away from the vessel beneath so as to not harm it.

Fig. 5: Local skin flaps are rotated avoiding unnecessary tension

The common digital nerve and its fascicles at the proximal aspect may have to be separated longitudinally using meticulous preparation technique. Redundant fibrous soft tissue should then be resected if necessary. The skin flaps are then sutured using

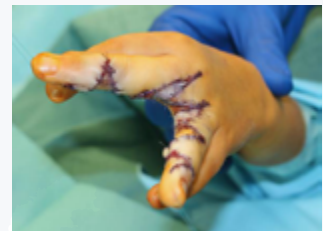

⁵ Bulic K. Long-term aesthetic outcome of fingertip reconstruction in complete syndactyly release. *J Hand Surg Eur Vol.* 2013 Mar;38(3):281-7.

absorbable sutures (Vicryl rapid 5-0) so as to close the defects as much as possible (Fig. 5). Thereafter, the defects which need to be closed with autologous full thickness skin grafts are measured. With our technique described in this report, usually two defects are present at each side of the finger. Skin grafts can be harvested from the wrist or forearm crease or groin, although we prefer the latter one due to the relatively huge skin excess and good cosmesis.

Fig. 6: Final situs after full thickness skin grafts are sewn in.

Prior to harvest, the defects are measured and incisions marked meticulously at the donor site. Furthermore, after harvest, it is imperative that the grafts are de-fatted to allow for proper wound healing. The grafts are sewn in with single sutures (we avoid running sutures to allow hematoma evacuation) under adequate, relatively strong tension (this is also necessary for proper recipient site-graft contact) (Fig. 6).



After final skin closure, the tourniquet is released, capillary refill verified and local anaesthesia injected. It is our preference to apply Jelonet™ paraffin gauze under the usual sterile gauze, and also a palmar long-arm cast longuette to allow for improved wound healing (for 10-14 days). These wounds heal better the more they are protected from daily life activities and motion in the immediate postoperative period. We prefer to change the dressings at the third postoperative day under conscious sedation because the first dressing change is always very stress- and painful for the young patients. Weekly dressing changes are mandatory until full healing of the grafts has been achieved. At some point during follow-up (usually 3 weeks postop), the parents are allowed and instructed to do home-bathing of the hand with sea salt. Later, scar care and massage are initiated. Follow-up investigations are aiming to assess digital motion and alignment. Separated syndactylies may rarely need further splinting (mainly complicated or complex cases) due to post-separation finger deviation.

Past Activities



EPOS 37TH ANNUAL MEETING 2018 IN OSLO 11-14 APRIL 2018 OSLO, NORWAY



Terje Terjesen, MD
Chairman of Local Organizing Committee
Norway

The 37th EPOS Annual Meeting was arranged in Oslo, Norway, 11-14 April, 2018. This was the first time the EPOS Meeting was arranged in Norway and we are honored and pleased to host this event which is so important to paediatric orthopaedic surgeons.

Based on the response from the attendants, we think the Meeting was a success both scientifically and socially. We were somewhat afraid that our colleagues from more southern parts of Europe would think it would be too cold to come to Norway in early April, but the opposite happened.



There were no less than 713 participants from 61 countries, which represented a record for EPOS Meetings. We received invaluable assistance with the planning and organization from our local Norwegian PCO, Congress-Conference AS, and its leader Øivind

Lie, who faced some challenges by taking over the arrangements at a very late date. Øivind and his colleagues were efficient and did an excellent job for EPOS. Moreover, there was a solid economic result of the Meeting; according to the EPOS President, the highest profit ever.

The congress started traditionally with the Pre-meeting course. The subject was "Developmental dislocation and dysplasia of the hip (DDH)". Although a vast amount of studies have been published on DDH, there are still several aspects where there is a lack of consensus. Well-known speakers from Europe and USA presented the latest news based on their own research and clinical experience. The lectures were published in Journal of Children's Orthopaedics as a Special Symposium issue (August 2018). We would like to thank the authors for their contributions and for keeping the time limit. Also great thanks to Mandy Webb, Managing Editor of the publishing company, who did a great job with the editing of the articles, which made it possible, probably for the first time, to publish the lectures the same year as the meeting.

For the main scientific program, we received more than 500 abstracts that were reviewed by members of EPOS Reading Committee under the leadership of Antonio Andreacchio.

Past Activities



EPOS 37TH ANNUAL MEETING 2018 IN OSLO 11-14 APRIL 2018 OSLO, NORWAY

They did a great job in selecting 236 abstracts for presentation: 113 podium presentations, 20 posters, and 103 e-posters. Furthermore, for the first time there were four Symposia arranged by four of the EPOS Study Groups. Similar symposia by other study groups are planned to take place at future EPOS Meetings.

Socially, we had the impression that the participants had a good time in Oslo, with the combination of modern city life and world-known museums and attractions. We got a lot of positive feedback from colleagues and actually have heard no complaints. Even the weather was on our side, especially at the Presidential dinner Tuesday night, where the beautiful colours of the evening sun and the panoramic view of the city were impressive. The warm and sunny weather continued throughout week. On Wednesday we were invited to a welcome reception at Oslo City Hall, famous for its rich decoration of wall and ceiling frescoes painted by the greatest artists in Norway.



At the official opening Thursday morning, we had a beautiful and touching performance with songs and dance by a group of children and adolescents of multiethnic backgrounds from 25 countries.



Instead of the traditional conference dinner, we modified the concept to a more informal get-together dinner in order to attract more of the young colleagues. We enjoyed a delicious Nordic signature buffet made by some of Norway's best chefs. In conclusion, the EPOS 2018 Oslo Meeting was a success, providing good publicity to EPOS, to the city of Oslo, and to Norwegian paediatric orthopaedics. I would like to express my warm thanks to all who contributed to the planning and preparations: the EPOS President Darko Anticevic and his board, the members of the Reading Committee, and the members of the Local Organizing Committee (LOC): Joachim Horn, Ivan Hvid, Vera Halvorsen, Stefan Huhnstock and Ola Wiig.

Thanks also to our sponsors from the Industry companies, and last but not least: warm thanks to Øivind Lie and his colleagues in Congress-Conference AS.

*On behalf of the Local Organizing Committee
Terje Terjesen, MD
Chairman of LOC*

Past Activities



5TH EPOS-EFORT BAT INSTRUCTIONAL COURSE, TRILOGY PART III PAEDIATRICS BASIC II | 17-19 OCTOBER 2018 VIENNA, AUSTRIA



Rudolf Ganger, MD

Local Host
Austria

The third part of the 5th EPOS-EFORT IC trilogy took place between 17th and 19th October 2018 in the Orthopaedic Hospital Speising Vienna.

The course included theoretical lectures, case presentations, debates, techniques in paediatric orthopaedics and workshops (research methods, femoral and tibial plates, spine instrumentation and gait analysis laboratory). Main topics were cerebral palsy and neuromuscular disorders, disorders of the spine, disorders of the upper limb, bone tumours, disorders of the knee and vascular skeletal infections including septic arthritis and osteomyelitis.

It was the 15th course in Vienna - Speising between 2011 and 2018 completing the 5th trilogy. 114 participants from 32 different countries participated at the course. At the end 55 participants finished the trilogy program, which allows them to apply for a membership at the European Paediatric Orthopaedic Society. Actually, from 2011 to 2018, 303 participants have finished the full program.

The faculty consisted of 14 international experts coming from 10 different countries: Antonio Andreacchio (Italy), Cristina Alves (Portugal), Ines Balaco (Portugal), Federico Canavese, Head of the Educational Committee of EPOS (France), Jaroslaw Czubak (Poland), Sebastian Farr (Austria), Rudolf Ganger (Austria), Ilkka Helenius

(Finland), Andreas Kranzl (Austria), Guy Molenaers (Belgium), Dror Ovadia (Israel), Ignacio Sanpera (Spain), Elke Vieweger (France), Thomas Wirth (Germany).



Again an electronic course-syllabus including the bulleted summary of the course was sent to the attendees before the course.

Our industry partners Orthopediatrics and K2M supported the course with workshops.

Personally, I would like to thank all the faculty members for their enormous contributions to the course, especially Federico Canavese as the new chair of the Educational Committee.

Dates of the upcoming 6th BAT trilogy courses

- Basis I 13-15 March 2019
- Trauma 16-18 October 2019
- Basic II 18-10 March 2020

Past Activities



13TH INTERNATIONAL CHINESE ORTHOPEDIC ASSOCIATION CONGRESS 21-24 NOVEMBER 2018 XIAMEN, CHINA



Federico Canavese, MD PhD
Pediatric Surgery Department
University Hospital Estaing
Clermont Ferrand, France

The XIII International Congress of the Chinese Orthopedic Association (COA) was held in Xiamen, China.

Xiamen historic heart and main urban area are located on Xiamen Island. The city, historically known as Amoy, is famous for its scenery and beaches. It is a modern, fast growing urban area of more than 4 millions habitants, not far from GuangZhou, Hong Kong and ShenZhen, three of the major Chinese cities.

Overall, more than 20000 orthopedic and traumatology specialists from all over China and nearby countries attended the 2018 COA meeting, and over 250 guest speakers - coming from all over the world and representing all orthopedics and traumatology subspecialties - joined the Chinese faculty. Moreover, the British Orthopedic Association represented United Kingdom as the 2018 COA Distinguished Guest Nation.

During the past four years the European Pediatric Orthopedic Society (EPOS) has continued to strengthen its relationships with COA. The participation of EPOS to the 2018 COA annual meeting was an ideal way of promoting further this idea. As for the past four years, EPOS had been given the opportunity to share the Pediatric Orthopedic Session with speakers from other countries. This year the Pediatric Orthopedic Session took place on Wednesday, November 21th,

and a heterogeneous group of speakers from Taiwan, South Korea, Hong Kong and United States joined the EPOS Faculty.

The 2018 EPOS representatives were EPOS 2nd Vice-President (2018-2019) Antonio Andreacchio from Italy, EPOS Past President (2013-2014) Deborah Eastwood from United Kingdom, EPOS Councillor Renata Pospischill from Austria and EPOS Junior Councillor Stephan Huhnstock from Norway. In addition to these four officially invited speakers, EPOS Educational Committee Chair Federico Canavese from France had the opportunity to join the EPOS Faculty having worked in GuangZhou, China during the past year.

The EPOS representatives shared the scientific program with Ji Shi Jun from China (Shantou University), Jack Chun-Yiu Cheng from Hong Kong (The Chinese University of Hong Kong), Hae-Ryong Song from South Korea (Korea University Medical Center Guro Hospital), and Hong Zhang from United States (Texas Scottish Rite Hospital, Dallas).

The Pediatric Orthopedic Session was coordinated and organized - with great skill and care, as in the past years - by Prof. Xuemin Lu from Beijing, China. It turned out to be a successful and highly stimulating session. More than 250 pediatric orthopedic surgeons, coming mostly from all over China and nearby countries

Past Activities



13TH INTERNATIONAL CHINESE ORTHOPEDIC ASSOCIATION CONGRESS | 21-24 NOVEMBER 2018 XIAMEN, CHINA



attended the Pediatric Orthopedic Session during which talks on idiopathic and syndromic scoliosis, lower limb deformities, amputations, DDH, Perthes disease, bone infections, clubfoot and skeletal dysplasia followed one another.

Each of the talks given sparked discussions amongst Chinese, European, Asian and American colleagues. The session was very enjoyable and academically very profitable.

Moreover, to meet people who are passionate about pediatric orthopedics was a very refreshing experience for all faculty members.

All attendees agreed it was a great thing to be a part of.

Besides the well-organized scientific program, the social program, including a visit to the beautiful Gulanyug Island, located in front of Xiamen, was very enjoyable.

Everything was perfectly well organized from the second EPOS guests arrived in Xiamen until their departure. In particular, EPOS leadership and members are proud of the relationships built with COA during the past few years and are looking forward to continuing close collaboration.

Thank you so much to COA leadership, to Prof. Xuemin Lu and to our Chinese friends for a wonderful and stimulating conference!

Upcoming Activities



EVENTS TAKING PLACE IN THE NEXT FEW MONTHS

JANUARY

*EPOS BAT Advanced Course
Hip Surgery
17-18 January 2019
Geneva, Switzerland
[More information](#)*

MARCH

*6th EPOS BAT IC Trilogy (Part I)
13-15 March 2019
Vienna, Austria
[More information](#)*

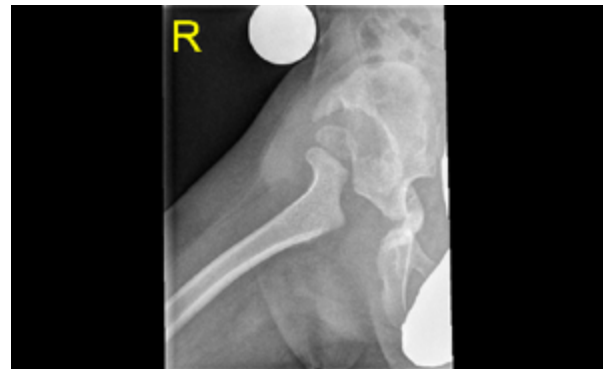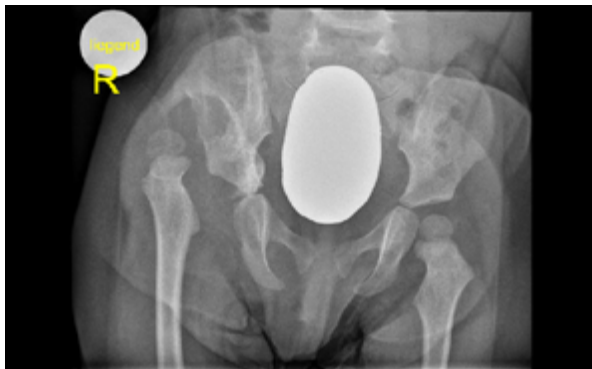
APRIL

*38th EPOS Annual Meeting
3-6 April 2019
Tel Aviv, Israel
[More information](#)*

Picture Quiz



WHAT IS YOUR DIAGNOSIS?



According to the above material, what is your diagnosis?

- A. *Postinfection dislocation of the right hip*
- B. *DDH*
- C. *Bone dysplasia*
- D. *Tumour of the right iliac bone*
- E. *Neurogenic dislocation of the right hip*

Pick one and send the answer to news@epos.org before 1 March 2019.

The *right answer with a short follow up* will be published in the next newsletter and/or on EPOS Facebook

Communication in Pediatric Orthopaedics 2018



IN THE AGE OF SOCIAL MEDIA, SHOULD YOU BE BOTHERED WITH E-NEWSPAPERS?



Renata Pospischill MD
EPOS Newsletter Editor
Consultant Paediatric Orthopaedic Surgeon
Orthopaedic Hospital Vienna Speising
1130 Vienna, Austria

"Content happens in the newsletter, and engagement happens on social media!"



*Tell us about your opinion regarding the EPOS E-newsletter
in times of facebook, twitter and instagram!*

*Do we still reach your attention with the content in the newsletter
or do you rather prefer instant information through social media channels?*

*We would appreciate your input!
Please give us a feedback to news@epos.org before 1 March 2019.*

